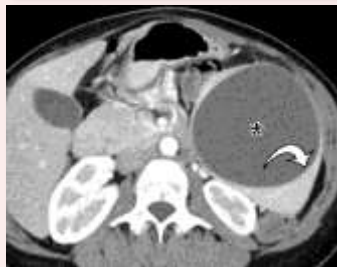
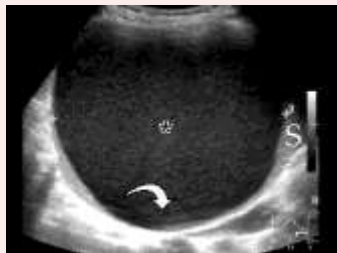
Algorithmic Approach to the Splenic Lesion Based on Radiologic-Pathologic Correlation

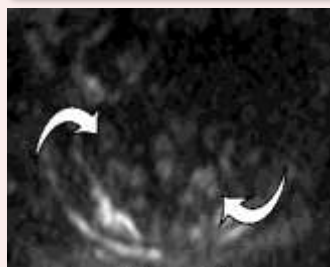
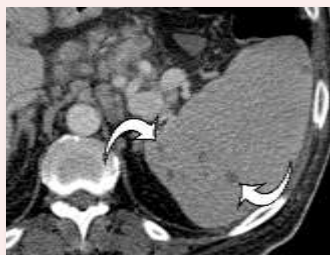Solitary cystic

Epithelial cyst



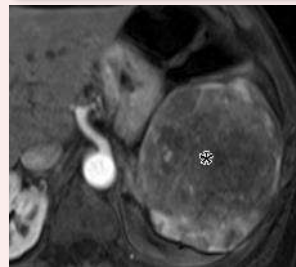
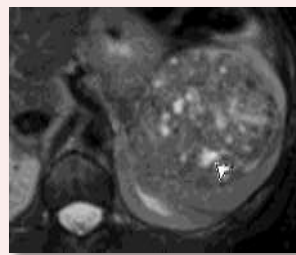
Multiple cystic

Fungal microabscesses



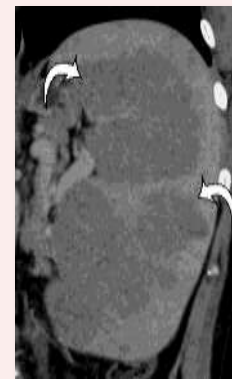
Solitary solid
(vascular)

Hemangioma



Solitary solid
(nonvascular)

Lymphoma



Multiple solid

Littoral cell
angioma

